

Pustular Psoriasis Masquerading Linear Naevoid Psoriasis:-A Case Report

Shrenikbalegar¹, Kumar Prateek², Shyam Sundar Chaudhary³, Meena Rinoobanwarilal⁴

Department Of Dermatology, Venereology, Leprosy. Rajendra Institute Of Medical Sciences
Bariatu, Ranchi.

Abstract:- Linear Psoriasis is a rare form of psoriasis characterised by linear array of lesions involving particular dermatome or along the blaschko lines. It may arise de-novo or as a part of Koebner phenomenon with other psoriatic lesions¹. It may resemble clinically to ILVEN (Inflammatory Linear Verrucous Epidermal Naevus)¹⁻². Hereby we are reporting a case of 39 year old male who initially presented with generalised pustular psoriasis but after treatment it emerged with linear verrucous papules resembling ILVEN and histologically with features of psoriasis.

Keywords:- Linear Psoriasis, ILVEN, Blaschko lines

I. Introduction

Linear psoriasis is an atypical form of Psoriasis often arises with chronic plaque type lesions elsewhere in the body.¹ It is very rare and even turn into pustular psoriasis. Differentiating it from other linear dermatoses is the key. There have been very few reports of linear psoriasis presenting in pustular form. We hereby report a case of Linear Psoriasis which turned to pustular psoriasis.

II. Case Report

A 39 year old male presented with 1 month history of Erythroderma with pustules all over the body. Examination revealed multiple pustules over erythematous base covering almost whole body with "lakes of pus". (figure 1) The patient was febrile and had a toxic look. He gave a history of sudden withdrawal of steroids a week back. Clinically we diagnosed as generalised pustular psoriasis. We started him on i.v fluids and i.v antibiotics and bland emollients. His general condition improved in 3 days and after confirming that his Cell counts, liver and renal function tests to be within normal limits, we put him on oral Azathioprine 100mg for 40 days. The lesions decreased and erythroderma resolved. But the lesions localised to inner aspects of both forearms, axillae, chest, and face. (fig 2,3,5) The morphology changed from pustules to verrucous scaly papules distributed linearly in the above mentioned sites (fig 2,3,5). We stopped Azathioprine and started him on i.m Methotrexate 30mg/week for 4 weeks. But the lesions didn't subside and remained resistant. Finally punch biopsy was sent for histopathological examination which showed moderately dense superficial perivascular lymphocytic infiltrate with papillary dermal hyperplasia. Epidermis showed marked psoriasiform hyperplasia, focal hypergranulosis, compact hyperkeratosis with foci of broad parakeratosis. (fig 4,5) In spite of anti-psoriatic treatment, the lesions didn't subside. Finally we started him on oral Acitretin 100mg/day and topical clobetasol-salicylic acid after which the lesions gradually decreased.

III. Discussion

Some consider linear psoriasis to be either synonymous with inflammatory linear verrucous epidermal nevus (ILVEN) or an invasion of pre-existing epidermal nevus by psoriasis due to koebnerisation.^{3,4} In our case the lesions clinically looked like ILVEN but histopathology was consistent with psoriasis. Even linear psoriasis can present as pustular form as in this case. The differentiation of linear psoriasis from other linear dermatoses is not easy. The combination of a complete history, careful skin examination, and histopathology are essential for making the correct diagnosis and insuring proper treatment⁷. The main differential diagnosis is ILVEN, clinical and pathological criteria for which were described by Altman and Mehregan in 1971⁶. In one study of 25 patients they defined the diagnostic criteria⁶ as: (i) early age of onset, (ii) female predominance, (iii) frequent involvement of the left lower extremity, (iv) substantial pruritus, (v) persistence of the lesions, and (vi) refractoriness to treatment. They described an inflammatory and psoriasiform appearance histopathologically, including areas of parakeratosis with loss of the granular cell layer and orthokeratosis with a prominent granular layer with a sharp demarcation. These features were absent in our patient so we ruled out ILVEN. Further clues supporting the diagnosis of psoriasis for this patient included the lack of pruritus, a good response to acitretin, and the histopathology which was consistent with psoriasis. Even the relatively rapid progression and

widespread distribution of the lesions was more consistent with psoriasis, rather than ILVEN. In conclusion we believe that linear psoriasis is a distinct entity and can turn into pustular form and can mimic ILVEN.

References

- [1] Rook's Textbook of Dermatology ch: 20.18 linear and zonal lesions in psoriasis.
- [2] Kerl H, Pachinger W. Psoriasis: odd varieties in the adult. *ActaDermVenereol(Stockh)* 1979; 59 (Suppl. 87): 90-4.
- [3] Bondi EE. Psoriasis overlying an epidermal nevus. *Arch Dermatol.* 1979;115:624-5.
- [4] Bologna JL, Orlow SJ, Glick SA. Lines of Blaschko. *J Am AcadDermatol.* 1994;31:157-90.
- [5] Ingram JT. The significance and management of psoriasis. *BMJ* 1954; ii: 823-8.
- [6] Atherton DJ, Kahana M, Russell-Jones R. Naevoid psoriasis. *Br J Dermatol* 1989; 120: 837-41.
- [7] Goujon C, Pierini AM, Thivolet J: Does linear psoriasis exists? *Ann DermatolVenereol* 108:
- [8] Thivolet J, Goujon C: Linear psoriasis and systematized epidermolytic nevus. *Arch Dermatol* 118: 285-286, 1982.
- [9] Sugai T, Shimotoge M, Saito T: Psoriasis and systematized epidermal nevus. *Arch Dermatol*
- [10] Ozkaya-Bayazit E, Akasya E, Buyukbabani N, et al.: Pustular psoriasis in a striking linear pattern. *JAm AcadDermatol* 42: 329-331, 2000.660, 1970.
- [11] Grosshans EM: AcquiredBlaschkolineardermatoses. *Am J Med Genet* 85: 334-337, 1999.
- [12] Ginarte M, Fernandez-Redondo V, Toribio J: Unilateral psoriasis: a case individualized by means of involucrin. *Cutis* 65: 167-170,2000.

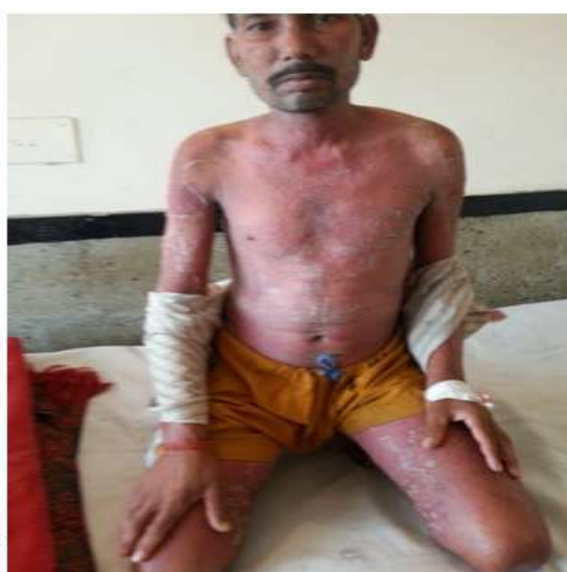
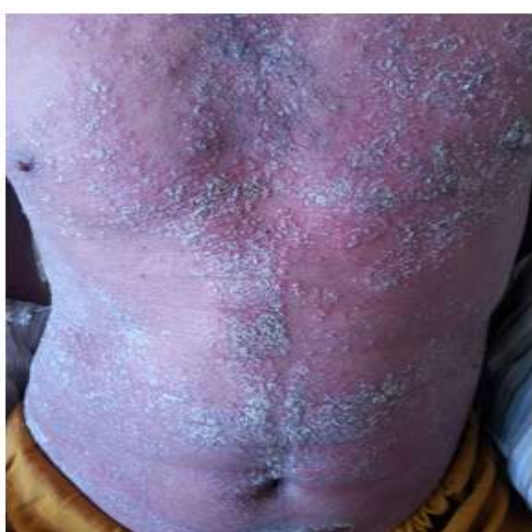
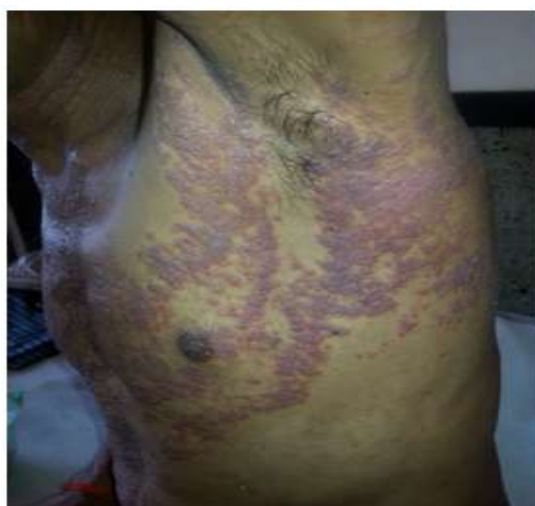FIG 1, 2



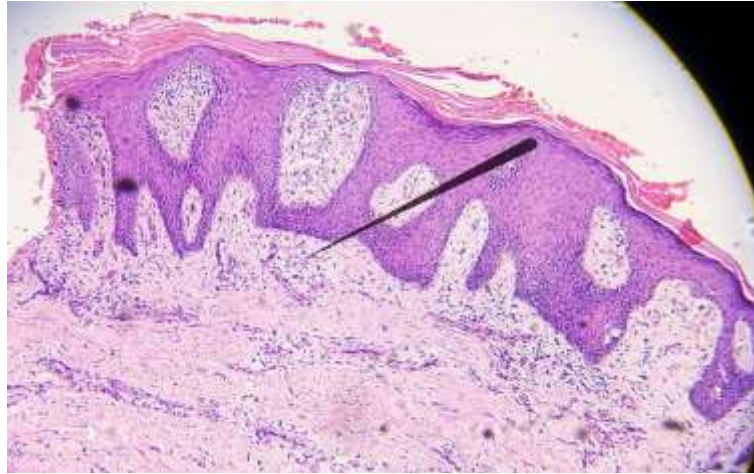

FIG 4

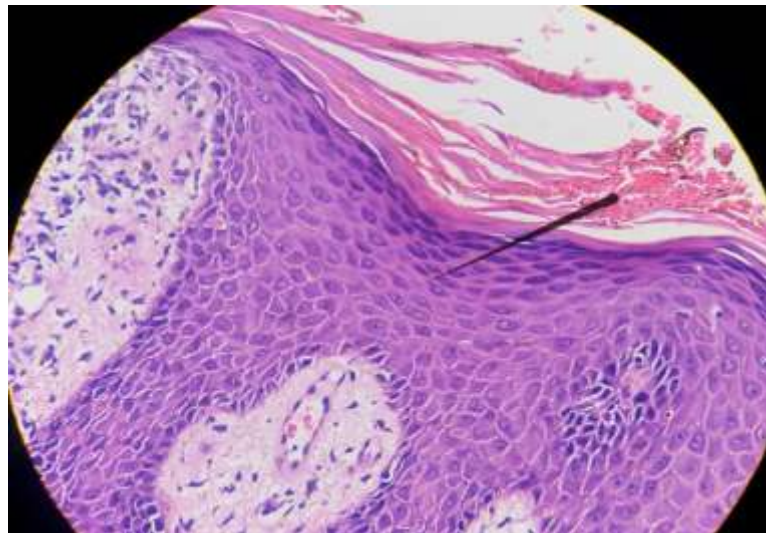


FIG 5

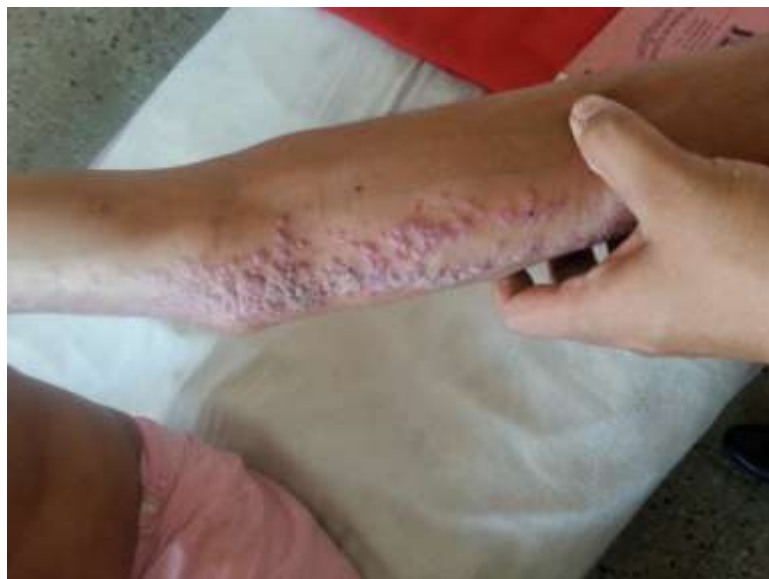

FIG 6